

SI Appendix

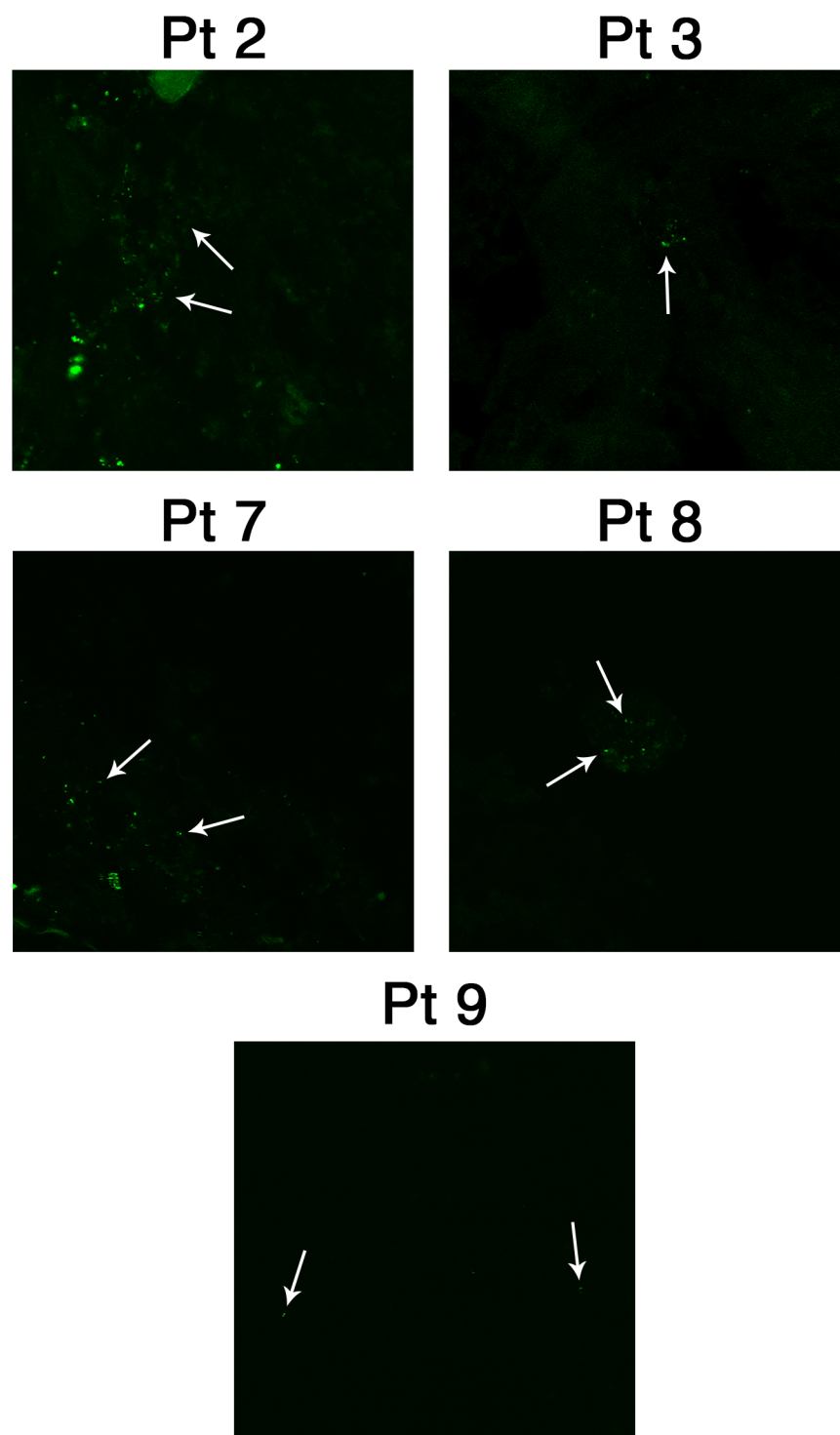


Fig. S1. Positive CPT signal in posttreatment tumor tissues. Posttreatment tumor images are shown for remaining patients not included in the main text. White arrows indicate examples of CPT signal.

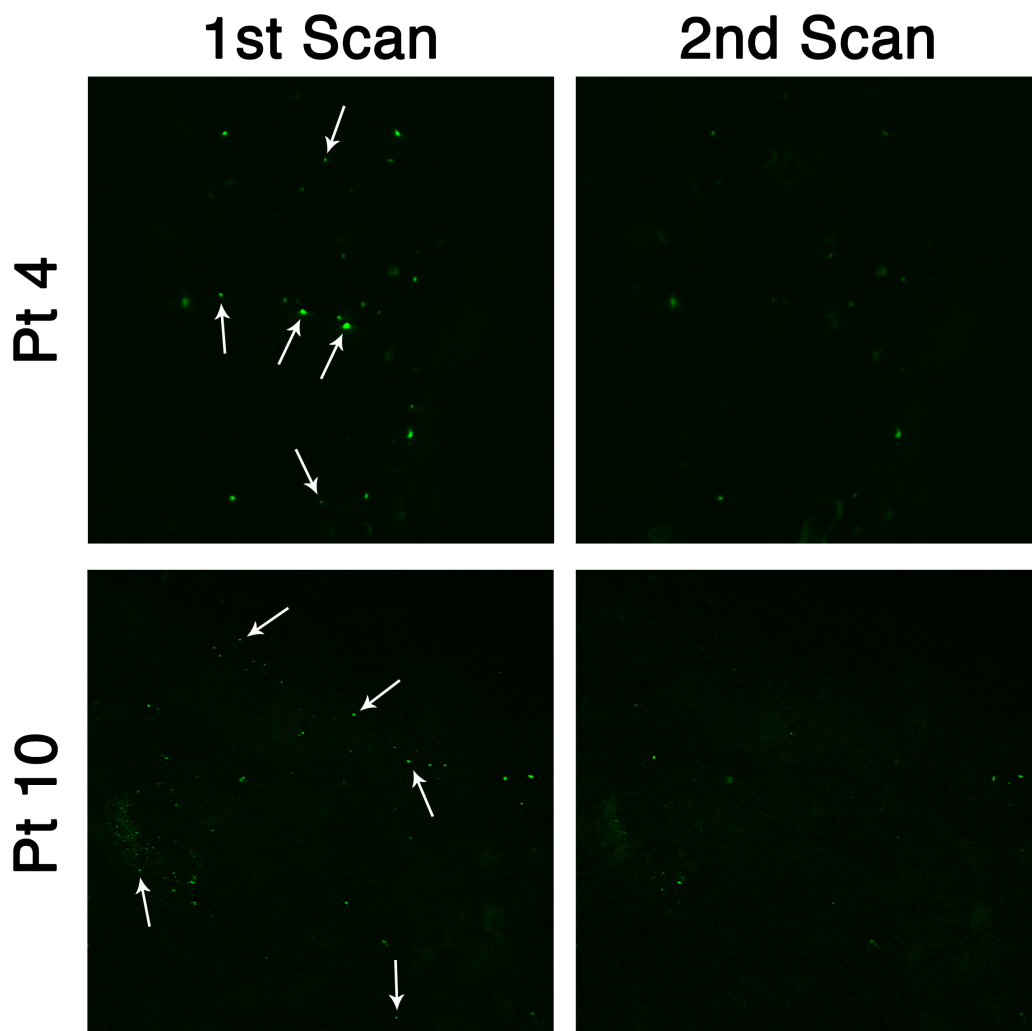
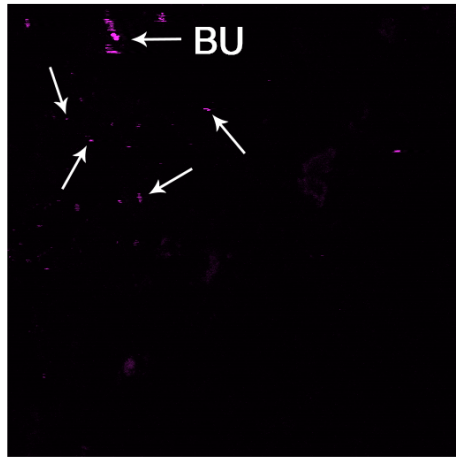


Fig. S2. CPT signal shows significant decrease with sequential laser scans. Points of positive CPT signal in the 1st scan which are absent in a 2nd scan of the same tissue area are indicated by white arrows. The majority of CPT signal is absent upon the 2nd laser scan.

1st Scan



2nd Scan

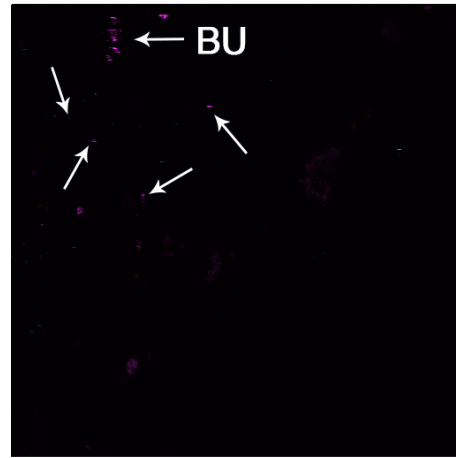
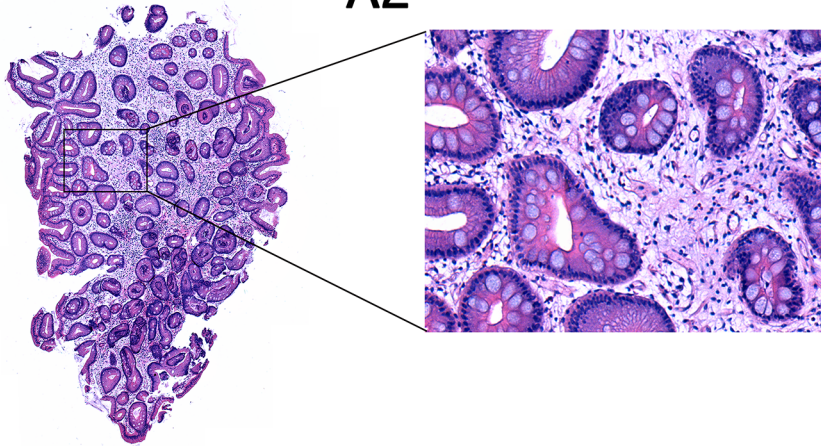


Fig. S3. Potential positive CPT signal (purple dots) in patient 8 posttreatment non-neoplastic tissue. Areas of potential CPT signal that did not diminish upon multiple confocal laser scans are indicated with white arrows. A bubble within the tissue section identified with a brightfield image is indicated with the BU label. The overall decrease in CPT signal in this tissue area was not as pronounced as that observed in the posttreatment tumor tissues (Fig. S2) so this tissue was not determined to contain definitive CPT signal.

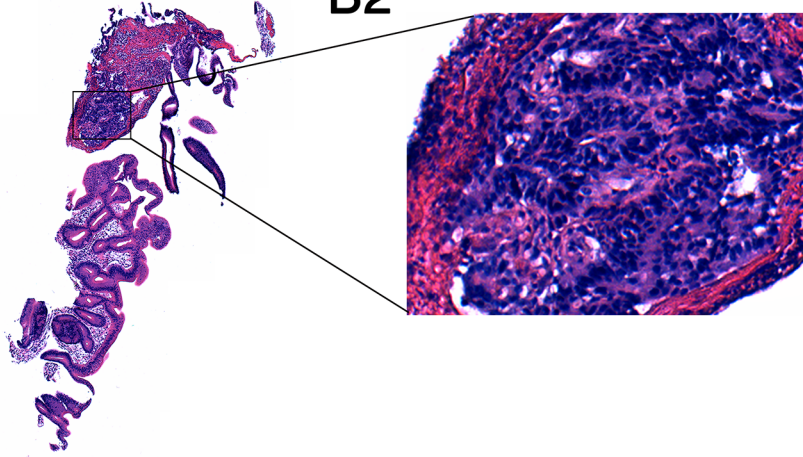
A1

A2



B1

B2



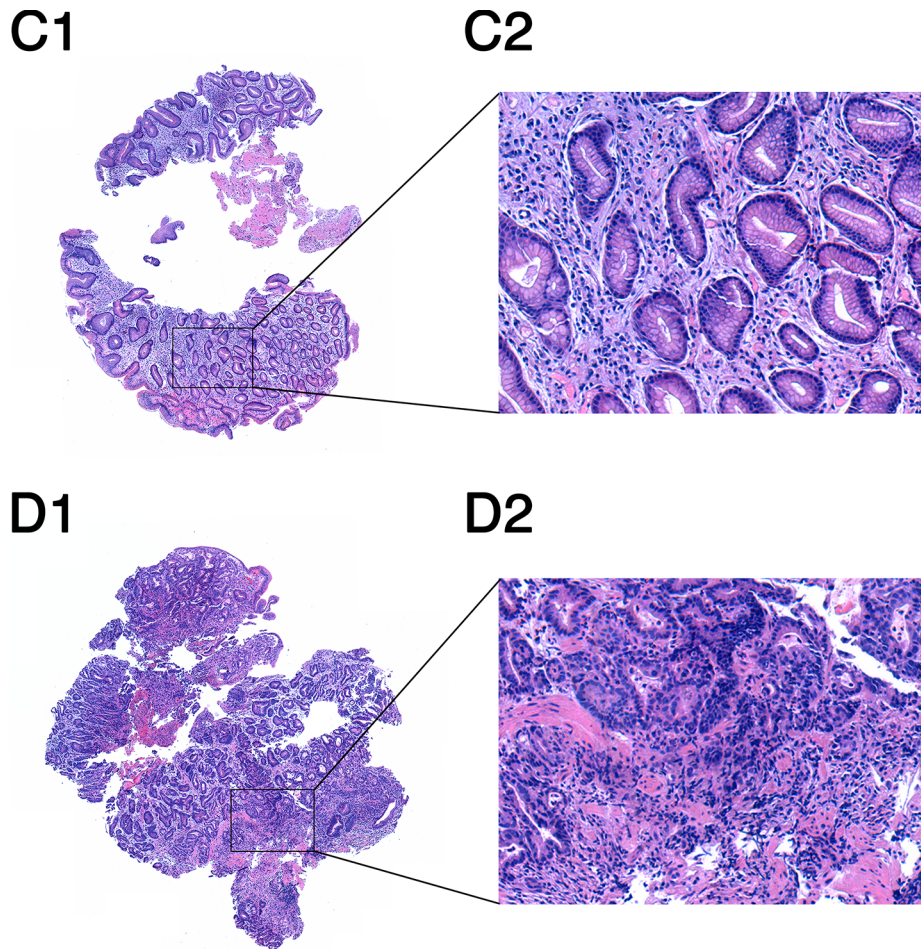


Fig. S4. H&E stain of biopsy series from a single patient. Sections of entire tissue biopsy for pre-treatment non-neoplastic (A1), pretreatment tumor (B1), posttreatment non-neoplastic (C1) and posttreatment tumor (D1) tissues are shown. The image in the right column (X-2) contains a high-magnification image of the area indicated by the box overlaying the corresponding full tissue section.